Anaesthesia 2013, 68, 961–965 doi:10.1111/anae.12251

Case Report

Hypnosis as sole anaesthesia for skin tumour removal in a patient with multiple chemical sensitivity*

E. Facco,[1] S. Pasquali,[2] G. Zanette[3] and E. Casiglia[4]

1 Professor of Anaesthesia and Intensive Care, 3 Assistant Professor, Department of Neurosciences, 4 Professor, Department of Medicine, University of Padua, and Italian Center for Clinical and Experimental Hypnosis, Turin, Italy
2 Registrar, Department of Oncological and Surgical Sciences, University of Padua, Padua, Italy

Summary

A female patient with multiple chemical sensitivity and previous anaphylactoid reactions to local anaesthetics was admitted for removal of a thigh skin tumour under hypnosis as sole anaesthesia. The hypnotic protocol included hypnotic focused analgesia and a pre-operative pain threshold test. After inducing hypnosis, a wide excision was performed, preserving the deep fascia, and the tumour was removed; the patient's heart rate and blood pressure did not increase during the procedure. When the patient was de-hypnotised, she reported no pain and was discharged immediately. Our case confirms the efficacy of hypnosis and demonstrates that it may be valuable as a sole anaesthetic method in selected cases. Hypnosis can prevent pain perception and surgical stress as a whole, comparing well with anaesthetic drugs.

Correspondence to: E. Facco
Email: enrico.facco@unipd.it
**Presented in part at the XIX International Hypnosis Congress, Bremen, October 2012*
Accepted: 3 March 2013
This article is accompanied by an Editorial by Pullman and Andrzejowski, pp 896–898 of this issue.

It is generally acknowledged that the history of hypnosis starts in the 18th century with Franz Anton Mesmer, and (though he is less well known) with Abbé Faria [1], who first recognised that it depended not on any animal magnetism, but on expectancy and the patient's cooperation. The core concept of hypnosis lies in focusing attention on an idea (mono-ideism) that can give rise to major psychological and physical phenomena, such as a massive increase in the hypnotised individual's pain threshold, specific haemodynamic changes [2–5], and clearly altered activity in particular areas of the brain [6–11]. This challenges the ruling mechanistic and reductionist approach in medicine, which sees the mind as an epiphenomenon of brain circuitry to be managed using pharmacological and interventional techniques only.

In his book *Mesmerism in India, and its Practical Applications in Surgery and Medicine*, published in 1846 (and quoted by Hammond [12]), Esdale reported a detailed description of over 300 major surgical operations performed under hypnosis as the only form of anaesthesia. Hypnosis was later abandoned, following the introduction of general anaesthetics (chloroform, ether and nitrous oxide), and only a handful of operations performed under hypnosis or self-hypnosis have been reported since the 1950s [13–18].

© 2013 The Association of Anaesthetists of Great Britain and Ireland

Multiple chemical sensitivity, also called idiopathic environment intolerance, is a relatively unknown syndrome, characterised by adverse effects occurring following exposure to low levels of chemical substances. It includes a variety of symptoms such as muscular weakness, migratory joint pains, psychological disturbances (such as anxiety and depression), respiratory distress (including chronic bronchitis and asthma), auto-immune disorders, and gastro-intestinal and genito-urinary tract dysfunction [19]. A cytochrome P_{450} gene polymorphism has also been suggested in multiple chemical sensitivity, but any relationship between the two has yet to be demonstrated [19–21].

Whatever its pathophysiology, multiple chemical sensitivity contra-indicates several drugs, including anaesthetics [19, 22]. We report an uncommon case of congenital cytochrome P_{450} deficiency and multiple chemical sensitivity with intolerance to local anaesthetics, who underwent surgery to remove a skin tumour using hypnosis as the sole anaesthetic.

Case report

A 42-year-old woman presented with a skin tumour in the right thigh. She had been suffering from so-called 'medically unexplained physical symptoms' [23] for several years, which were eventually diagnosed as multiple chemical sensitivity at the Environmental Health Center in Dallas. She was also diagnosed with a congenital cytochrome P_{450} deficiency and had a history of anaphylactoid reactions to local anaesthetics, and had been warned strongly against using such drugs. This clinical picture prompted the choice of hypnosis for anaesthesia to avoid undue risks.

The patient had detected a clinically atypical nevus (diameter 1 cm). A shave biopsy was performed suggesting a Spitz tumour requiring a wide excision and hypnosis was considered to allow surgery. The planned procedure was a skin incision with a 1-cm margin around the lesion and removal of the fatty tissue below the tumour, preserving the deep fascia. The patient gave her informed consent and underwent two hypnotic training sessions before her operation to verify her hypnotisability and the analgesic capability of her hypnotic state.

In the first session, hypnosis was induced using eye closure and verbal suggestions with relaxing cues to induce a sense of wellbeing. Then the Stanford Hypnotic Susceptibility Scale Form C (SHSS-C) was administered [24]; the patient scored 8 (on a 0–12 scale), classifying her as moderately hypnotisable. In the second session, hypnotic focused analgesia was obtained after hypnotic induction. The hypnotic protocol adopted was the same as for dental analgesia, as described in detail elsewhere [5], which includes performing a pain threshold test with a dental pulp stimulator (Digitest^{TM} electric pulp tester; Parker, Farmingdale, NY, USA) to check whether a patient is able to develop a full analgesia under hypnosis – an essential condition for successful surgery (see Video S1).

Hypnotic focused analgesia was induced at the right low arch, suggesting an inferior alveolar nerve block had been performed, while touching the depression between the zygomatic arch and the mandibular notch. Then it was enhanced by repeatedly touching and scraping with a finger the right cheek over the mandible and suggesting immediately after that the perceived sensation in the right side was due to the local anaesthesia, spreading to the right inferior teeth. A repeated suggestion of neglect of the right low arch, including teeth, gum, mucosa and skin was administered. The patient's hypnotic focused analgesia was then modified to transfer it to her right thigh; it was easily obtained by suggesting the performance of an epidural block, while touching the lumbar spine, instead of the mandible. To reduce the time needed for further inductions, post-hypnotic conditioning was administered at the end of the first training session. During the second training session, the patient reached full dental pulp analgesia (tested on the first right premolar), experiencing no pain after a maximal electrical dental pulp stimulation. Her thigh operation was consequently scheduled for a few days later.

There is no evidence that pre-operative testing in these patients reduces the risk of adverse drug reaction [22].

On the day of surgery the patient was taken to the operating room, where routine anaesthetic monitoring was started and intravenous cannulation performed. Resuscitation drugs and equipment were prepared. Hypnosis was induced and hypnotic focused analgesia at the thigh was suggested. Ten minutes after the induction of hypnosis, a wide skin incision (6 cm × 3 cm

 © 2013 The Association of Anaesthetists of Great Britain and Ireland

width and about 3 cm depth) was performed with preservation of deep fascia; diathermy was not used, to avoid unnecessary painful stimuli. The tumour was removed and the operation ended 20 min after the initial skin incision (see Video S2). During the operation the patient did not report pain, nor was there any haemodynamic change, apart from a transient increase in heart rate during positioning before skin incision. Indeed, during the operation there was a progressive decrease of both heart rate and systolic blood pressure (Fig. 1). At the end of surgery the patient was dehypnotised. She confirmed the absence of pain and reported that she was happy the procedure had been undertaken without the need for any anaesthetic drugs. She was not amnesic and had a clear memory of all surgical phases. She also reported she had been very fearful before hypnotic induction, and afraid of possible pain and complications leading to failure of the operation, a feeling that reached its maximum at the moment of positioning; this feeling quickly disappeared as soon as she perceived skin incision as a light tactile non-painful stimulus. She also had recall of the application of deep stitches, perceived as a painless sensation of stretching. Immediately after the operation the patient was discharged without needing any further recovery. When she was contacted by telephone the same evening, she reported mild background pain in the afternoon, which transiently reached peak values of 8 on a 0–10 verbal rating scale, but not so strong as to prevent her daily activities, partly spent playing with her daughter. The histological examination disclosed a Spitz tumour.

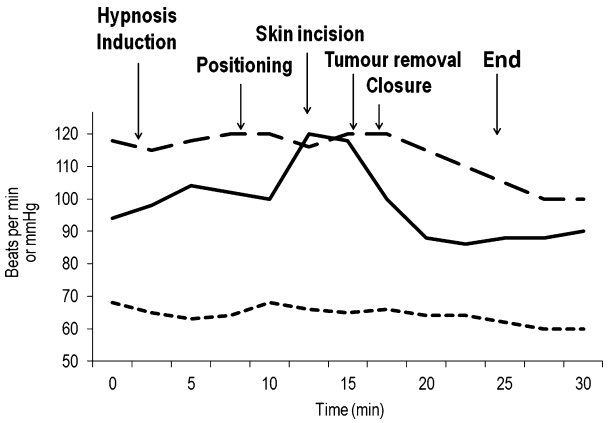

Figure 1 Heart rate (---) and systolic (– – –) and diastolic (—) blood pressure during skin tumour removal with hypnosis as the sole anaesthetic.

Discussion

Multiple chemical sensitivity belongs to a still misunderstood, ill-defined group of syndromes including physical and psychological components, also called 'medically unexplained physical symptoms' [23, 25, 26]; their classification as separate entities focusing on environmental (multiple chemical sensitivity, idiopathic environment intolerance), rheumatologic (fibromyalgia), toxic or post-viral factors (chronic fatigue syndrome) is questionable. Whatever its pathophysiology, patients with multiple chemical sensitivity have a difficult life, being prone to harmful systemic reactions triggered by various chemicals in the environment as well as by several kinds of drugs. Apart from a few case reports, only one article has been published on anaesthesia in patients with multiple chemical sensitivity, including a review of the literature as well as the warnings reported by special-interest internet sites [22]. The authors conclude that there is no evidence of risks of severe complications from the administration of anaesthetics, apart from drugs for which there is a history of adverse effects.

In our patient, a clear history of anaphylactoid reactions following local anaesthesia was present, leading us to avoid their use and choose a non-pharmacological technique, that is, hypnosis. Drugs and equipment for pharmacological anaesthesia were available at the time of operation, to manage any possible problem, including failure of hypnosis. They included both intravenous agents (such as propofol, midazolam, remifentanil) and volatile anaesthetics, as it was not known whether any particular anaesthetic drugs were more likely than others to produce a reaction.

The scheduled pre-operative hypnotic training sessions allowed us to check both her hypnotisability and her analgesic capability. The Stanford Hypnotic Susceptibility Scale Form C, which has been validated and widely used for patients' assessment in research on hypnosis, does not provide an estimate of a patient's analgesic capability, a crucial factor in surgery; this can only be indirectly inferred from the overall hypnotisability [27, 28], with the empirically ill-grounded assumption that the greater the suggestibility, the

© 2013 The Association of Anaesthetists of Great Britain and Ireland

greater the hypnotisability and the greater the analgesia. Instead, we purposefully decided to check the analgesic capacity directly, using an electrical dental pulp stimulator, according to our previous published protocol [5]. This procedure has two main advantages: it is much faster and simpler than the use of the Stanford Hypnotic Susceptibility Scale Form C; and it provides a direct, accurate assessment of analgesia.

Our case clearly shows that even a moderately hypnotisable subject can reach full analgesia. This suggests the need to reappraise this topic considering the following aspects: (i) as warned at the beginning of the Stanford Hypnotic Susceptibility Scale Form C and also more recently emphasised by its authors [29], the Stanford Hypnotic Susceptibility Scale is a measure of suggestibility rather than hypnotisability and its relationship with hypnosis is strictly inferential and poorly empirically founded; (ii) there is a groundless, anecdotal belief among hypnologists that full analgesia can be reached by no more than 15–20% of the population, roughly corresponding to the rate of highly hypnotisable (or simply suggestible) subjects, while in our previous study we found full analgesia in 45% of cases [5]; and (iii) the increased pain threshold in hypnosis depends on several factors and thus, on the adopted hypnotic protocol. The use of hypnotic focused analgesia and suggestions of neglect are much more effective than neutral hypnosis (see [5] for further details); a subject's strong motivation might also help to reach his/her maximal hypnotic capability.

It is worth noting that our patient did not feel any pain during surgery, despite full recall of the operation and the sensations she felt during each surgical step. Together with her Stanford Hypnotic Susceptibility Scale score and with the fear-related increase of heart rate during positioning, this shows that hypnosis was not 'deep', and that the use of hypnotic focused analgesia allowed development of full analgesia at least partly independent of other hypnotic actions. If so, a direct estimate of pain threshold according to our protocol seems to be more appropriate and relevant than the Stanford Hypnotic Susceptibility Scale in anaesthesia and pain medicine.

Finally, our case confirms the effectiveness of hypnosis in pain control, showing that hypnosis as a sole anaesthetic may be a valuable tool in selected cases, even in the era of powerful pharmacological anaesthesia. Furthermore, this case demonstrates for the first time hypnotically induced cardiovascular stability during surgery, making hypnosis a true analgesic tool. In fact, it was able to block not only pain perception but also surgical stress as a whole, raising comparison with pharmacological anaesthesia.

Although the use of hypnosis in anaesthesia may appear irrelevant at present, it remains a valuable tool as an adjunct to pharmacological anaesthesia, thus possibly improving the cost/benefit ratio, as previously emphasised by Wobst [30]. His conclusions are worth repeating here: "*If hypnosis and autosuggestions provide clinical benefit, they do so without the need for equipment or drugs. What other therapeutic measure appears so devoid of increased cost and demonstrable adverse effects? Personal attention to the patient, emotional support, positive suggestions, and even hypnosis are readily available, safe, inexpensive and attractive measures that might improve the care of our patients*".

The increasing tendency towards negative communication in clinical practice may yield a nocebo effect, which, in turn, may worsen pain perception – the opposite of the therapeutic target [31, 32]. We believe that it is now time to reappraise our mechanistic paradigm, with its 'objectivity fascination' and 'subjectivity neglect'. Relying on drugs and interventional tools only, while unwittingly worsening the patient's anxiety and pain perception by inappropriate communication, may lead to the need for higher doses of drugs to compensate for inappropriate behaviour. This is scientifically, philosophically and ethically unconceivable, and calls for reintroducing the world of subjectivity in biomedicine and behavioural competence in anaesthetists' and other caregivers' professionalism.

Acknowledgements

Published with the written consent of the patient.

References

1. Carrer L. *Jose Custodio de Faria: Hypnotist, Priest and Revolutionary*. Victoria, Canada: Trafford, 2004.
2. Casiglia E, Mazza A, Ginocchio G, et al. Hemodynamics following real and hypnosis-simulated phlebotomy. *American Journal of Clinical Hypnosis* 1997; **40**: 368–75.
3. Casiglia E, Rossi A, Tikhonoff V, et al. Local and systemic vasodilation following hypnotic suggestion of warm tub bathing. *International Journal of Psychophysiology* 2006; **62**: 60–5.

 © 2013 The Association of Anaesthetists of Great Britain and Ireland

4. Casiglia E, Schiavon L, Tikhonoff V, et al. Hypnosis prevents the cardiovascular response to cold pressor test. *American Journal of Clinical Hypnosis* 2007; **49**: 255–66.
5. Facco E, Casiglia E, Masiero S, Tikhonoff V, Giacomello M, Zanette G. Effects of hypnotic focused analgesia on dental pain threshold. *International Journal of Clinical and Experimental Hypnosis* 2011; **59**: 454–68.
6. Faymonville ME, Boly M, Laureys S. Functional neuroanatomy of the hypnotic state. *Journal of Physiology Paris* 2006; **99**: 463–9.
7. Derbyshire SW, Whalley MG, Stenger VA, Oakley DA. Cerebral activation during hypnotically induced and imagined pain. *Neuroimage* 2004; **23**: 392–401.
8. Schulz-Stubner S, Krings T, Meister IG, Rex S, Thron A, Rossaint R. Clinical hypnosis modulates functional magnetic resonance imaging signal intensities and pain perception in a thermal stimulation paradigm. *Regional Anesthesia and Pain Medicine* 2004; **29**: 549–56.
9. Hofbauer RK, Rainville P, Duncan GH, Bushnell MC. Cortical representation of the sensory dimension of pain. *Journal of Neurophysiology* 2001; **86**: 402–11.
10. De Pascalis V, Magurano MR, Bellusci A. Pain perception, somatosensory event-related potentials and skin conductance responses to painful stimuli in high, mid, and low hypnotizable subjects: effects of differential pain reduction strategies. *Pain* 1999; **83**: 499–508.
11. Pyka M, Burgmer M, Lenzen T, et al. Brain correlates of hypnotic paralysis-a resting-state fMRI study. *Neuroimage* 2011; **56**: 2173–82.
12. Hammond DC. Hypnosis as sole anesthesia for major surgeries: historical and contemporary perspectives. *American Journal of Clinical Hypnosis* 2008; **51**: 101–21.
13. Dias MM. The 1st surgical operation under hypnosis. *Revista brasileira de cirurgia* 1963; **46**: 399–400.
14. Monteiro AR, De Oliveira DS. Tonsillectomy under hypnosis. *Medicina Cirurgia Farmàcia* 1958; **26**: 315–20.
15. Rausch V. Cholecystectomy with self-hypnosis. *American Journal of Clinical Hypnosis* 1980; **22**: 124–9.
16. Wain HJ. Reflections on hypnotizability and its impact on successful surgical hypnosis: a sole anesthetic for septoplasty. *American Journal of Clinical Hypnosis* 2004; **46**: 313–21.
17. Bowen DE. Transurethral resection under self-hypnosis. *American Journal of Clinical Hypnosis* 1973; **16**: 132–4.
18. Botta SA. Self-hypnosis as anesthesia for liposuction surgery. *American Journal of Clinical Hypnosis* 1999; **41**: 299–301.
19. De Luca C, Raskovic D, Pacifico V, Thai JC, Korkina L. The search for reliable biomarkers of disease in multiple chemical sensitivity and other environmental intolerances. *International Journal of Environmental Research and Public Health* 2011; **8**: 2770–97.
20. Bolt HM, Roos PH, Thier R. The cytochrome P-450 isoenzyme CYP2E1 in the biological processing of industrial chemicals: consequences for occupational and environmental medicine. *International Archives of Occupational and Environmental Health* 2003; **76**: 174–85.
21. Keown-Eyssen G, Baines C, Cole DE, et al. Case-control study of genotypes in multiple chemical sensitivity: CYP2D6, NAT1, NAT2, PON1, PON2 and MTHFR. *International Journal of Epidemiology* 2004; **33**: 971–8.
22. Fisher MM, Rose M. Anaesthesia for patients with idiopathic environmental intolerance and chronic fatigue syndrome. *British Journal of Anaesthesia* 2008; **101**: 486–91.
23. Richardson RD, Engel CC Jr. Evaluation and management of medically unexplained physical symptoms. *Neurologist* 2004; **10**: 18–30.
24. Weitzenhoffer AM, Hilgard ER, Kihistrom JF. *Stanford Hypnotic Susceptibility Scale Form C*. Stanford, USA: Stanford University Press, 1962.
25. Hausteiner C, Bornschein S, Zilker T, Henningsen P, Forstl H. Dysfunctional cognitions in idiopathic environmental intolerances (IEI) – an integrative psychiatric perspective. *Toxicology Letters* 2007; **171**: 1–9.
26. Bornschein S, Forstl H, Zilker T. Idiopathic environmental intolerances (formerly multiple chemical sensitivity) psychiatric perspectives. *Journal of Internal Medicine* 2001; **250**: 309–21.
27. Dufresne A, Rainville P, Dodin S, et al. Hypnotizability and opinions about hypnosis in a clinical trial for the hypnotic control of pain and anxiety during pregnancy termination. *International Journal of Clinical and Experimental Hypnosis* 2010; **58**: 82–101.
28. Levitan AA, Harbaugh TE. Hypnotizability and hypnoanalgesia: hypnotizability of patients using hypnoanalgesia during surgery. *American Journal of Clinical Hypnosis* 1992; **34**: 223–6.
29. Weitzenhoffer AM. Scales, scales and more scales. *American Journal of Clinical Hypnosis* 2002; **44**: 209–19.
30. Wobst AH. Hypnosis and surgery: past, present, and future. *Anesthesia and Analgesia* 2007; **104**: 1199–208.
31. Colloca L, Benedetti F. Nocebo hyperalgesia: how anxiety is turned into pain. *Current Opinion in Anesthesiology* 2007; **20**: 435–9.
32. Hauser W, Hansen E, Enck P. Nocebo phenomena in medicine: their relevance in everyday clinical practice. *Deutsches Ärtzeblatt International* 2012; **109**: 459–65.

Supporting Information

Additional Supporting Information may be found in the online version of this article:

Video S1. Video of pre-operative training session showing induction of hypnotic focused analgesia and check of pain threshold.

Video S2. Video of surgical removal of a skin tumour under hypnosis as sole anaesthesia.

© 2013 The Association of Anaesthetists of Great Britain and Ireland